



# The Effect of a specific Vitamin Supplement containing L-methylfolate (Ocufolin forte) in Patients with Neo-vascular Age-Related Macular Degeneration

Tatjana Josifova <sup>1</sup>, Katarzyna Konieczka <sup>2,3</sup>, Andreas Schötzau <sup>4</sup>, Josef Flammer <sup>2</sup>

<sup>1</sup> Eye Clinic Orasis, Department for Medical and Surgical Retina, Reinach, Switzerland

<sup>2</sup> Department of Ophthalmology, University of Basel, Switzerland

<sup>3</sup> Glaucoma Eye Practice Dr. K. Konieczka, Basel, Switzerland

<sup>4</sup> Statistical Consulting, University of Basel, Switzerland

**Study design:** 27 eyes of 27 patients were treated with 3 aflibercept injections at one-month intervals. Of these, 15 patients additionally received 1 capsule of Ocufolin® forte per day (Ocufolin group), the other 12 patients served as a control group.

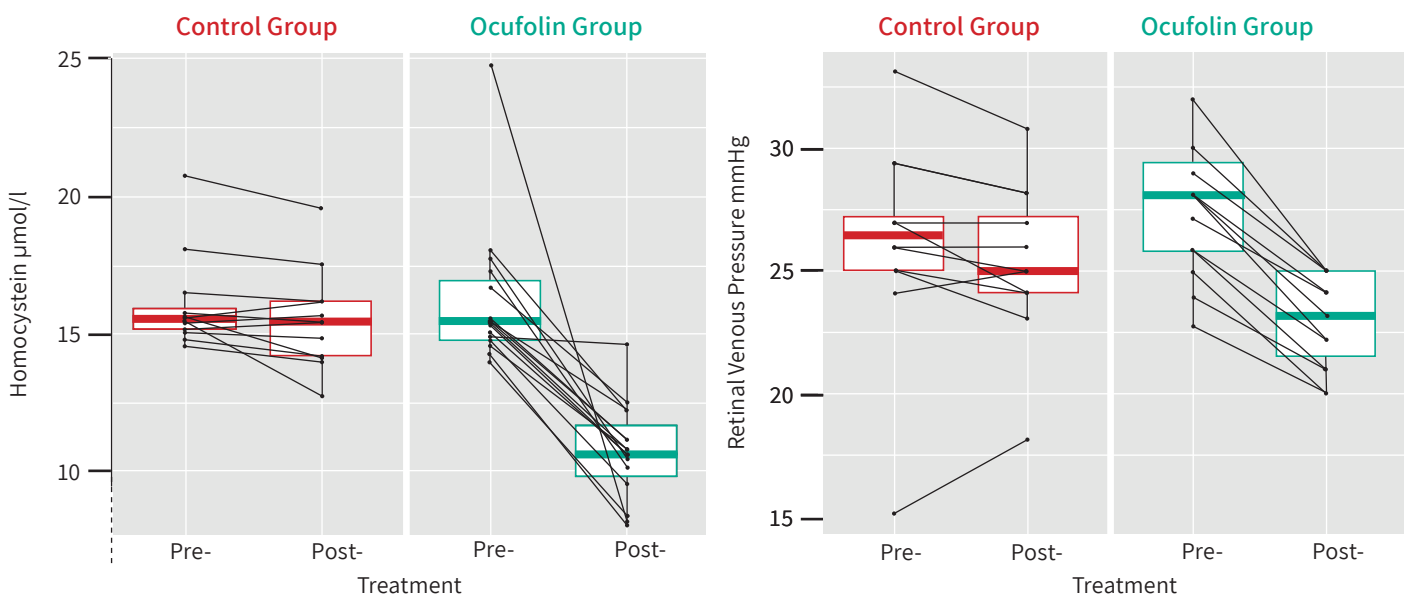
**Study parameters:** In addition to the standard examinations, the following tests were carried out at the start of the study and after 4 months: Determination of homocysteine in the blood, measurement of retinal venous pressure (RVP), OCTA imaging of the retina.

**Inclusion criteria:** nAMD patients who had been pre-treated with anti-VEGF between 6 and 23 times in the affected eye and had a homocysteine level of >12 µM/l and an RVP > 8 mm Hg above the IOP.

**Results:** The ocufolin group had an average age of 76 and the control group of 77 years.

- The homocysteine blood level was significantly reduced in the ocufolin group, but not in the control group ( $p < 0.001$ ).
- The retinal venous pressure decreased in both groups, but significantly more in the Ocufolin group ( $p < 0.001$ ).
- CNV type 1 and 2 activity was reduced more in the Ocufolin group than in the control group.

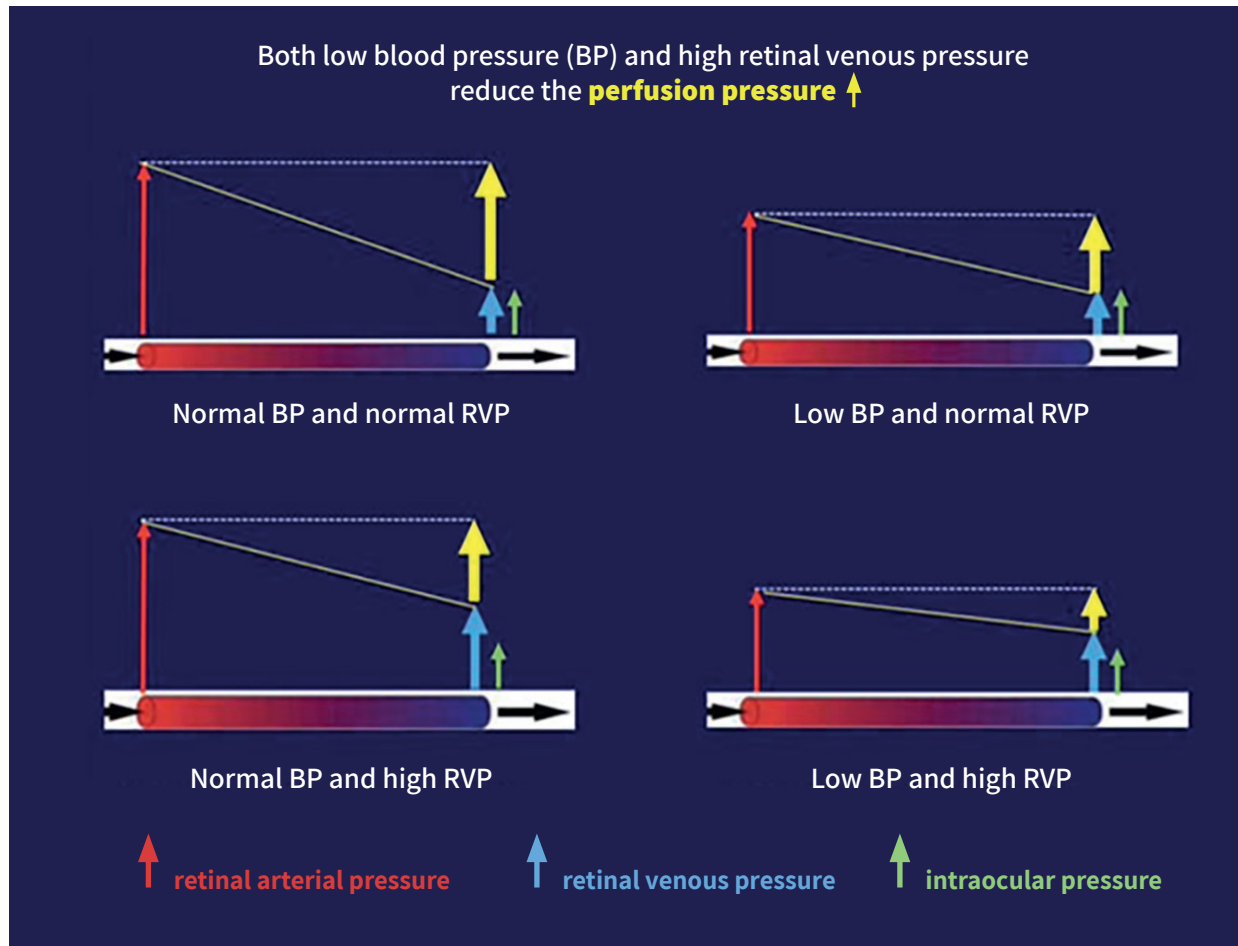
### Effect of Ocufolin® forte



### Conclusion

The additional intake of 1 capsule of Ocufolin® forte per day was well tolerated without side effects and significantly reduced the two important risk factors homocysteine and retinal venous pressure, CNV activity was reduced as well. We recommend further studies, also on patients in an earlier phase of the disease and also over a longer period of time.

Influence of the retinal venous pressure (RVP) on the perfusion pressure (PP) and thus indirectly on the blood flow to the retina and optic disc



This graph symbolizes the arterial pressure at the entrance to the eye and the venous pressure at the exit from the eye in healthy people, people with low blood pressure (BP) or increased retinal venous pressure (RVP) or both. The result is a reduction in perfusion pressure and thus a reduction in the pressure gradient which is the driving force of blood flow.

Modified from: Konieczka K. Glaukompatient mit Verdacht auf Flammer-Syndrom. Klin Monatsbl Augenheilkd 2024; 241: 335



**Increased RVP reduces blood flow to the retina and of the optic nerve head.**